

whom were treated with streptokinase, while 7 with no treatment acted as controls. Reperfusion was seen in 5/13 patients treated with streptokinase, and in 2/7 controls. Reperfusion correlated with significant neurological improvement in 6/7 cases. In three cases no definite abnormality was identified on either scan (lacunar infarcts or TIAs), and all patients made excellent recoveries. In two cases of subcortical infarction the area of hypoperfusion increased slightly when the patient made significant clinical improvement. All other patients had persisting hypoperfusion, and had poor neurological recovery. We conclude that early neurological improvement is related to a normal initial scan, or to early reperfusion in cortical infarcts. The later hypoperfusion seen in two patients with subcortical infarcts may be due to diaschisis. It is too early to correlate these results with thrombolytic administration and more patients are needed to confirm these results.

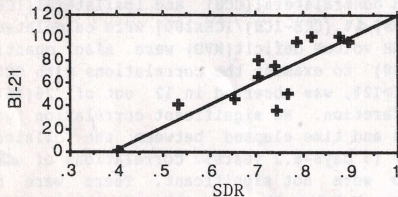
No. 224

SPECT BLOOD FLOW IN STROKE: ASSOCIATION WITH CLINICAL PROGNOSIS. Z. Rattner, PB Fayad, H Dey, LM Brass and PB Hoffer, Yale University School of Medicine, New Haven, CT.

Studies examining the prognostic value of SPECT blood flow imaging in stroke have used differing methods and obtained mixed results. We report the outcome of a pilot study to determine the utility of early SPECT in predicting stroke prognosis.

Thirteen patients with cerebral infarction were imaged by SPECT (20 mCi Tc-99m-HMPAO) within 48 hours of presentation. Clinical evaluation included a Toronto stroke scale on day 0 (TSS-0), representing the neurologic deficit, and a Barthel index on day 21 (BI-21), representing residual functional disability. SPECT lesions were characterized by multiple parameters, including volume and a stroke density ratio (SDR), the average lesion counts/voxel divided by the counts/voxel in a comparable normal contralateral region.

SDR correlated strongly with BI-21.



TSS-0 also correlated with BI-21, but one patient with a mild initial clinical deficit and a dense lesion on SPECT did poorly. Stroke volume alone did not correlate with prognosis.

These preliminary results suggest that a small SDR, which corresponds on images to a clearly visible defect of any size, predicts a less favorable clinical outcome. By providing prognostic information, in addition to confirming stroke location and extent, SPECT blood flow imaging may be a useful tool to identify candidates for early aggressive therapeutic intervention.

No. 225

NEUROLITE® AS AN AID IN THE DIAGNOSIS AND LOCALIZATION OF STROKE. R.C. Walovitch, R. Sakowski, K. Hall, M. Woodin, J. Biegel, T. Hua and N. LaFrance. The Du Pont Merck Pharmaceutical Co.

Two essentially identical multi-center trials were conducted to determine the sensitivity and specificity of Neurolite® kit for the preparation of Tc99m-Bicisate (ECD) as an aid in the diagnosis and localization of stroke. In each trial, European (02) and North American (03), at least 100 evaluable stroke patients and 30 neurologically normal volunteers had a Neurolite® SPECT imaging study. All evaluable SPECT images were read institutionally by the principal investigator and three blinded readers who did not participate in the trial. The location of perfusion defects, which was noted independent of clinical assessment, was compared to the location of the functional defect determined from the overall clinical impression excluding the Neurolite® study. Neurolite® was safe and well tolerated in all subjects. Neurolite® sensitivity and specificity percentages for localizing stroke are listed below:

Study #	Institutional		Blinded Read	
	02	03	02	03
Sensitivity	87	86	74 (78)	61 (73)
Specificity	97	98	88	98

In general, the sensitivity and specificity of Neurolite® was the same in all phases of stroke. Inter-reader reliability was very

consistent in both blinded reads. Lower sensitivity in the blinded reads is expected and was partly attributed to the blinded readers lack of familiarity with the multiple format of SPECT images. Sensitivity was similar for all types of strokes except for lacunar which showed decrease sensitivity both institutionally and in the blinded reads. The lower blinded read sensitivity of study 03 disappeared when lacunar strokes, which had a higher incidence in the 03 study, were excluded (value in parentheses). In conclusion, Neurolite® SPECT images are sensitive and act as a specific marker in localizing brain regions which are functionally impaired due to stroke.

Computer and Instrumentation: Young Investigators Symposium



3:30-5:00

Session 39

Room 502A

No. 226

QUANTIFICATION OF THE HUMAN BASAL GANGLIA VIA ITERATIVE RECONSTRUCTION. J.A. Fessler, W. L. Rogers, N. H. Clinthorne, G. D. Hutchins, and R. A. Koepp. University of Michigan, Ann Arbor, MI.

This study examined the accuracy of iterative reconstruction methods for a clinical task: quantifying benzodiazepine receptor density via Flumazenil (FMZ) concentration within the putamen and globus pallidus (GP). These small brain structures may be involved in Huntington's disease. Based on literature for simple geometric phantoms, we hypothesized that iterative reconstruction would outperform filtered back-projection (FBP) for this clinical task.

Assigning FMZ activity values obtained from autoradiography to a complex brain phantom, we performed realistic simulations of PET measurements that included the effects of nonuniform attenuation, accidental coincidences, spatially varying geometric detector response, detector errors, and counting statistics (1M events, 7% randoms). The sinogram dimensions were matched to our CTI 931 scanner in the unwobbled mode, with 512 detectors and 6.2mm crystal width.

Reconstructing the measurements via ramp FBP, the %RMS errors in putamen uptake were 5.1% (left) and 6.4% (right). For the GP, the errors were 36% and 53%. The errors are largely due to bias, i.e. to spillover from high activity in cortex or low activity in background. Thus, applying a Hanning window further degraded the %RMS performance. The iterative methods investigated were: Polite's ML-IB EM algorithm with internal corrections for attenuation and randoms, post-smoothed versions thereof, and a previously reported weighted penalized-likelihood method that can accommodate structural side information obtainable from high resolution anatomic images. For each method, the %RMS errors were computed from 50 independent realizations. After 400 iterations of ML-IB, the putamen RMS errors were 12%, and the globus pallidus errors were 15% and 31%. Interestingly, at 400 iterations the putamen errors were increasing (due to variance increase of EM) yet the GP errors were still decreasing due to bias recovery. This concurs with previous reports that the optimal number of iterations for EM is object size dependent. (The GP is much smaller than the putamen.) Applying a 9mm FWHM Gaussian smoother to the ML-IB reconstructions gave 5% and 6% RMS errors for the putamen, comparable to filtered backprojection, but increased the GP RMS errors to 39% and 60%. Using 800 iterations of the weighted penalized-likelihood approach with perfect side information, the GP errors were reduced to 6% and 11%, with a small increase in the putamen errors.

This study demonstrates that the benefits of iterative methods significantly depend on object size and surrounding activity. For small regions such as the globus pallidus, the iterative methods showed substantial reductions in percent RMS error.

No. 227

KINETIC MODELING OF TEBOROXIME USING DYNAMIC SPECT IMAGING. A.M. Smith, G.T. Gullberg, F.L. Datz, and P.E. Christian. The University of Utah, Salt Lake City, UT.

Fitting compartment models to dynamically acquired data is possible with the development of multi-detector SPECT systems. The purpose of our study was to determine if regional kinetic parameters of blood volume fraction and exchange between blood and tissue compartments will give a more sensitive indication of myocardial perfusion defects than visual evaluations of static images. Studies were performed on canine models using 15 mCi of the heart agent teboroxime (CardioTec, SQUIBB) and a three detector SPECT system (Picker PRISM 3000). Complete sets of sixty projections (each 64x64 matrix) were obtained every 10 seconds for 15-30 minutes, and blood samples were drawn from the femoral artery every 10 sec for the first 5 min, then every minute for the last 10-25 min. The projections were reconstructed and tracer concentration versus time curves were formed from regions of interest (ROIs) in the left intraventricular cavity (blood) and the left